
PATIENT

Xixie Boss

SPECIES

Canine

BREED

CKCS

SEX

Female Spayed

AGE

12 years

WEIGHT

14.2lbs; 6.4kgs

INTERPRETED BY

 Maggie Machen Lamy,
 DVM, DACVIM
 (Cardiology)

IMAGING PERFORMED BY

 Wavelength Vet
 Services

HOSPITAL NAME

 Brookwood Animal
 Clinic

REFERRING VET

Dr. Loomis

INVOICE

21792

DATE

11/1/21

PRESENTING CLINICAL SIGNS

 History: Grade 3/6 systolic heart murmur. Seen for inappetence and pale gums, vomited 4 days ago.
 -Current medications: Vetmedin 10mg tab 1/4 t BID
 -Abnormal PE/Chem/CBC/UA Results: Inflammatory leukogram.

ECHOCARDIOGRAM FINDINGS

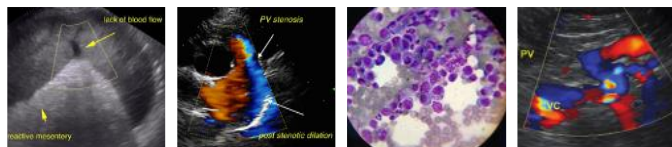
2D, m-mode, color flow and doppler imaging is available. Mild diffuse thickening of mitral valve leaflets with mild prolapse into the left atrial lumen. Mild to moderate eccentric mitral regurgitation with mild left atrial dilation. Normal MR velocity. Normal LV diameter with adequate myocardial function. The tricuspid valve appears mildly thickened with septal prolapse and mild tricuspid regurgitation. Velocity consistent with early pulmonary hypertension. Normal right atrial and ventricular diameter and morphology indicating no overt evidence of pulmonary arterial hypertension. The pulmonic and aortic valves are normal in morphology and mobility. Normal pulmonic and aortic outflow velocities with laminar flow. A small jet of flow is seen entering the distal pulmonary artery past the level of the valve. Spectral doppler through the region shows a primarily systolic jet; however, continuous flow is not ruled out. No obvious aortic or pulmonic insufficiency. No pericardial or pleural effusion noted. No obvious cardiac masses.

CARDIAC CHART

CANINE CARDIAC PARAMETERS	MR VMAX (m/s)	TR VMAX (m/s)	LA/AO (Boon method)	LA/AO (Heart Base; Swe)	FS (%)	EF (%)	EPSS (cm)
NORMAL PARAMETER	4.5-5.5	<2.7	1.3	<1.6	28-40	40-100	<0.6
PATIENT	5.4	2.7	NM	1.4	44	76	0.28
CANINE CARDIAC PARAMETERS	HR (BPM)	AV VMAX (m/s)	PV MAX (m/s)	BODY WEIGHT (kg)	LA 2D short axis Base view (cm)	LVIDd Avg; 2D and m-mode short axis (cm)	LVIDs Avg; 2D and m-mode short axis (cm)
NORMAL PARAMETER	50-100	0.7-1.7	0.7-1.6	BELOW	BELOW	BELOW	BELOW
PATIENT	NM	0.9	0.55	6.4	2.0	3.3	1.8
*Normal chamber parameters expressed as a mean value (SD)							
BODY WEIGHT DEPENDENT PARAMETERS							
*Note: All measurements based upon multi-modal images and methods. An average value is reported.							
				5	1.40 (4.5)	2.74 (5.2)	1.60 (4.7)
				10	1.50 (3.8)	3.27 (3.5)	2.06 (3.1)
				15	1.83 (2.0)	3.71 (2.4)	2.43 (2.1)
				20	2.02 (1.9)	4.14 (2.2)	2.80 (2.0)
				25	2.18 (2.4)	4.48 (2.9)	3.10 (2.5)
				30	2.33 (3.3)	4.83 (3.9)	3.39 (3.4)
				35	2.48 (4.3)	5.17 (5.0)	3.69 (4.5)
				40	2.62 (5.2)	5.48 (6.1)	3.96 (5.4)
				50	2.88 (7.1)	6.07 (8.3)	4.46 (7.4)

INTERPRETATION OF THE FINDINGS & FURTHER RECOMMENDATIONS

Chronic degenerative valve disease causing mild to moderate mitral and mild tricuspid regurgitation. Lack of significant left atrial enlargement indicates the current risk for complication is low. Early pulmonary hypertension is noted which should be monitored going forward. Finally, there is a small, atypical jet seen in the diastole pulmonary artery. This is potentially a very small



PATIENT

Kixie Boss

PDA; however, the abnormality is certainly hemodynamically insignificant. No additional issues are noted in this study.

SPECIES

Canine

While typically no cardiac medications are indicated with this degree of disease, the finding of borderline left heart dimensions and early pulmonary hypertension may benefit from Pimobendan assuming the medication is well tolerated. No additional medications are indicated at this time. Assessment of progression in the future will help predict long term prognosis, which is highly variable at this stage (B1). Omega fatty acid supplementation and mild salt restriction may be of some long-term benefit. Monitor for development of a cough, labored breathing, exercise intolerance or collapse episodes.

BREED

CKCS

SEX

Female Spayed

Anesthetic risk is considered mild if needed. Cardiac protective drug choices (opioid/benzodiazepine premedication, propofol or alfaxalone induction, isoflurane gas) are recommended. Pre-oxygenate for 5-10 minutes prior to induction. Monitor for arrhythmias, hypotension, and hypoxia both intra and post-operatively and intervene as necessary. Mild IV fluid restriction is recommended to avoid fluid overload. Avoid heart rate stimulating drugs such as atropine unless clinically indicated.

AGE

12 years

Recommend conservative monitoring with a recheck echocardiogram in 6 months, sooner if any development of clinical signs.

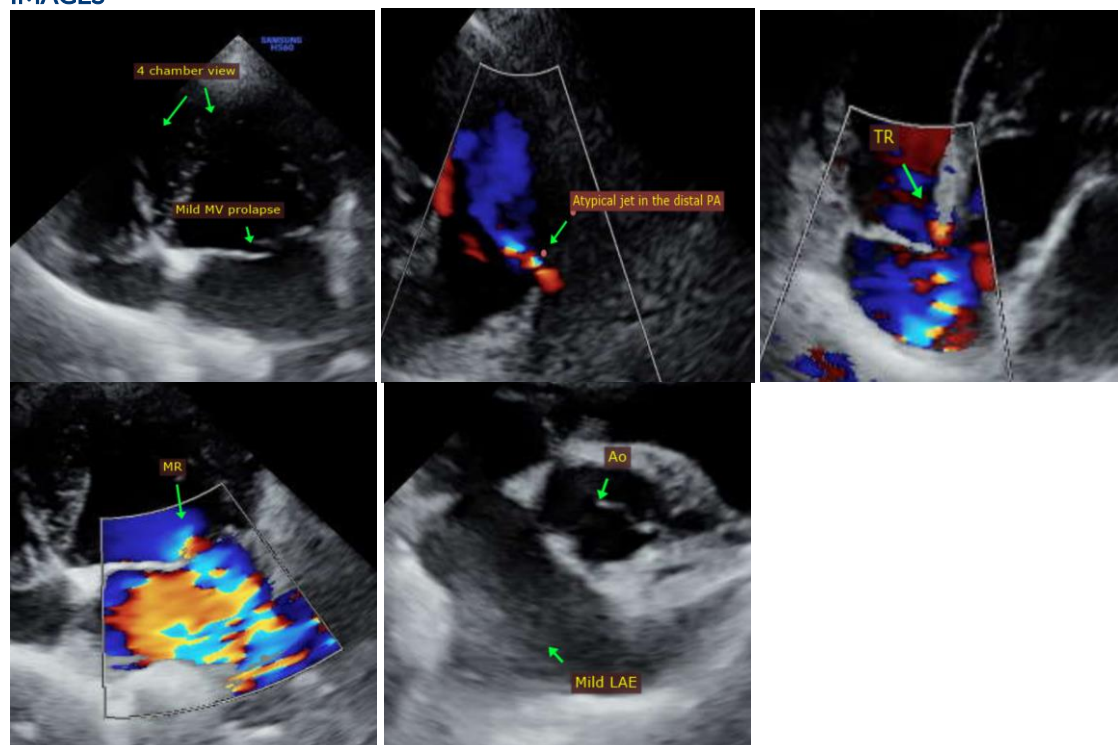
WEIGHT

14.2lbs; 6.4kgs

INTERPRETED BY

Maggie Machen Lamy,
DVM, DACVIM
(Cardiology)

IMAGES



IMAGING PERFORMED BY

Wavelength Vet
Services

HOSPITAL NAME

Brookwood Animal
Clinic

REFERRING VET

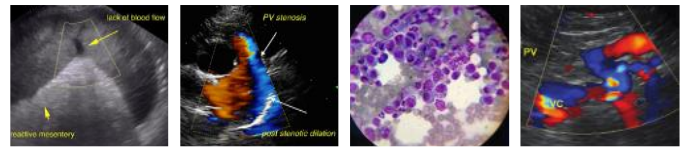
Dr. Loomis

INVOICE

21792

DATE

11/1/21



PATIENT

Kixie Boss

The information and recommendations provided are based on the images presented by the referring veterinarian. No evaluation can be communicated regarding pathology that was not visible in the image/video clips provided.

SPECIES

Canine

Thank you for this referral. This report was generated using transcription software, and minor dictation errors may be present. If the clinical or image interpretation does not parallel your findings or if I can be of any further assistance, please contact me.

BREED

CKCS

Maggie Machen Lamy, DVM
Diplomate of the American College of Veterinary Internal Medicine (Cardiology)
info@sonopath.com

SEX

Female Spayed

AGE

12 years

WEIGHT

14.2lbs; 6.4kgs

INTERPRETED BY

Maggie Machen Lamy,
DVM, DACVIM
(Cardiology)

**IMAGING
PERFORMED BY**

Wavelength Vet
Services

HOSPITAL NAME

Brookwood Animal
Clinic

REFERRING VET

Dr. Loomis

INVOICE

21792

DATE

11/1/21